

## Squamous Cell Carcinoma of the Septal Mucosa Secondary to Nasal Piercing?

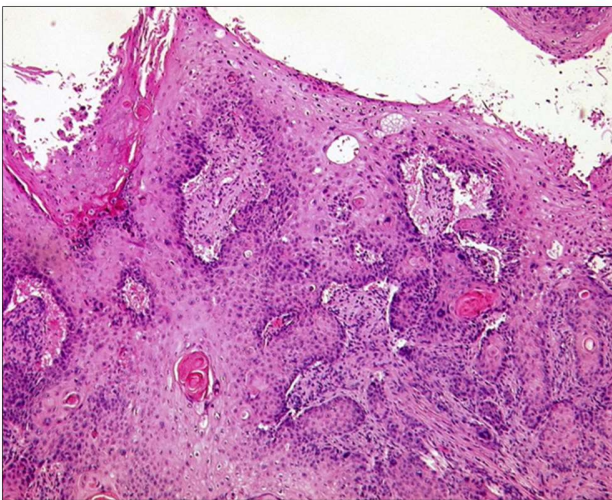
BJ Folz\*

\*Department of Otorhinolaryngology, Head and Neck Surgery, Karl-Hansen Medical Center, Bad Lippspringe, Germany.

Received July 09, 2019; Accepted August 06, 2019; Published January 06, 2020

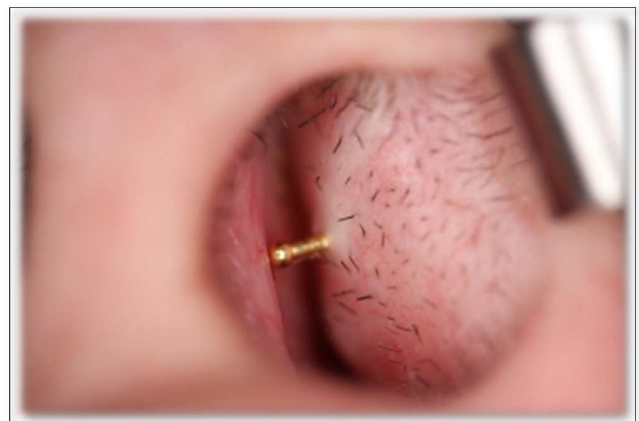
### CASE REPORT

A 55 year old lady was referred to us with a biopsy proven squamous cell carcinoma of the nasal septum. She had noticed a chronic irritation of the septal mucosa and bleeding from the left nostril some weeks before she consulted an ENT-surgeon. The referring surgeon had seen a growth on the left nasal septum and had taken a biopsy. Biopsy showed a squamous cell carcinoma (**Figure 1**). The colleague sent the lady to our service for surgical therapy.



**Figure 1.** H&E stain of a specimen of the left nasal septum of the presented patient. The stain shows nest of squamous epithelial cells invading the stroma.

On admission we saw an otherwise healthy 55 year old lady. The only remarkable finding was a piercing on the left nasal ala, which protruded into the left nasal cavity and touched the nasal septum exactly at the area, where the biopsy was taken (**Figures 2 and 3**).

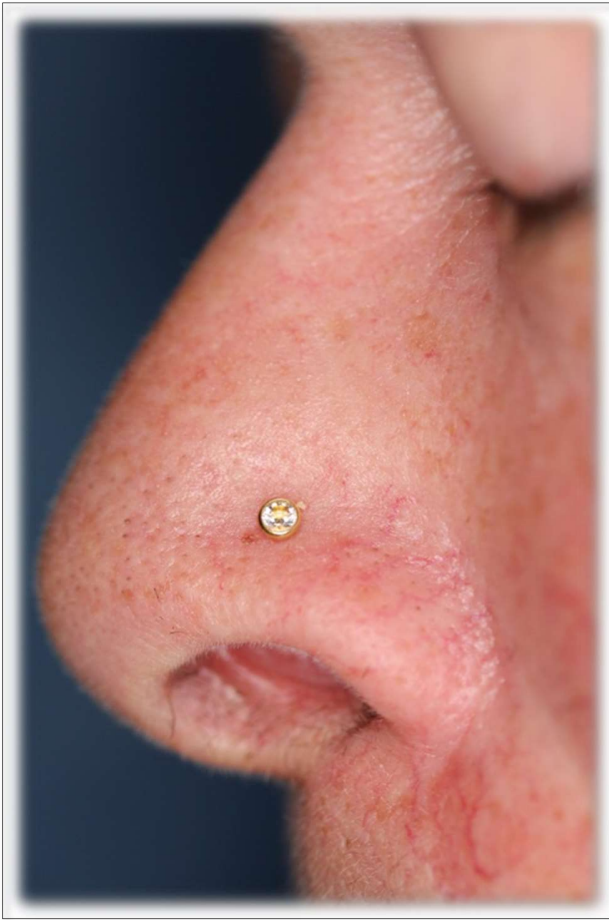


**Figure 2.** “Lovers view” of the left nostril showing the piercing stud, touching the septal mucosa. This chronic irritation in combination with chemicals, diluted from the metal of the ornament, might have contributed to the development of the carcinoma.

**Corresponding author:** Prof. Dr. Med. BJ Folz, Department of ORL, HNS, Karl Hansen Medical Center Antoniusstr. 19, D-33175 Bad Lippspringe, Germany, Tel: +49-5252-954302; E-mail: b.j.folz@medizinisches-zentrum.de

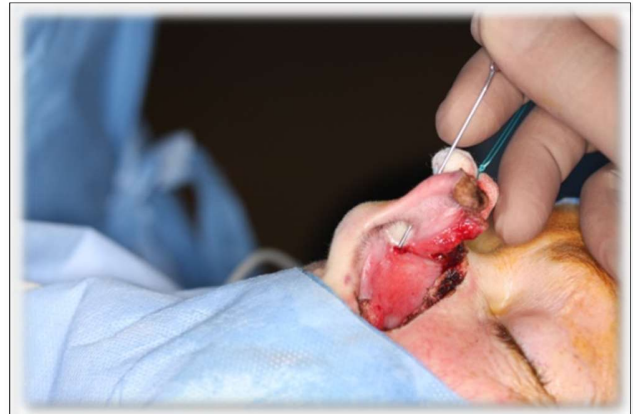**Citation:** Folz BJ. (2020) Squamous Cell Carcinoma of the Septal Mucosa Secondary to Nasal Piercing? Int J Clin Case Stud Rep, 2(1): 76-78.

**Copyright:** ©2020 Folz BJ. This is an open-access article distributed under the terms of the Creative Commons Attribution License, which permits unrestricted use, distribution, and reproduction in any medium, provided the original author and source are credited.



**Figure 3.** The piercing ornament *in situ*. There were no irritations of the outer skin or the piercing canal. The septal mucosa however did not respond well to the chronic irritation.

The lady underwent surgery by an open approach (**Figure 4**). The nasal ala was incised and the left-sided nasal cavity was exposed. The respective nasal mucosa was excised and the defect was closed with a free skin graft. Margins had been assessed intraoperatively as frozen sections. Neither the frozen sections nor the final histology report showed remnants of the carcinoma. The postoperative healing process was undisturbed; oncology follow-up did not show any signs of recurrent or metastatic disease. The lady is now 4 years free of disease.



**Figure 4.** Resection of the septal mucosa via an external approach. The nasal ala is incised similar to a lateral rhinotomy approach, giving the best exposure of the tissue. The probe is in the piercing canal, again pointing at the area, where the carcinoma had emerged. The respective mucosa was excised and the denuded site was covered with a skin graft. Healing was undisturbed and the patient is now free of disease for more than 4 years.

#### DISCUSSION

In the head and neck region complications secondary to piercing of the nose are not uncommon. Most frequently the ear is affected, but the nose is second in line [1]. Most frequently patients develop acute inflammation, embedding, pyogenic granuloma or other types of granulomatous disease [2,3]. Normally removal of the ornaments and debridement of eventual excess granulomatous tissue, aided by local or systemic antibiotic therapy, leads to complete healing. Rarely cases of infective endocarditis secondary to nose piercing complications have been described [4]. A few cases of basal cell carcinoma at the piercing site have been described in recent years [5,6]. However, to the best of our knowledge, this is the first case, in which nasal piercing may have played a role in the pathogenesis of a squamous cell carcinoma of the nasal mucosa. So far, the prognosis seems to be good, but more cases should be collected and monitored to gain more information about this additional hazard of nose piercing.

#### CONCLUSION

Piercing of the nose can lead to acute and chronic inflammation, pyogenic granuloma, granulomatous perichondritis and infective endocarditis. Recently also malignomas of the skin have been described in association with nasal piercing. This is eventually the first case, in which nasal piercing contributed to the development of a squamous cell carcinoma of the nasal mucosa.

**REFERENCES**

1. Folz BJ, Lippert BM, Kuelkens C, Werner JA (2002) Jewellery-induced diseases of the head and neck. *Ann Plast Surg* 49: 264-271.
2. Kumar Ghosh S, Bandyopadhyay D (2012) Granuloma pyogenicum as a complication of decorative nose piercing: Report of eight cases from eastern India. *J Cutan Med Surg* 16: 197-200.
3. Folz BJ, Lippert BM, Kuelkens C, Werner JA (2000) Hazards of piercing and facial body art: A report of three patients and literature review. *Ann Plast Surg* 45: 374-381.
4. Ramage IJ, Wilson N, Thomson RB (1997) Fashion victim: infective endocarditis after nasal piercing. *Arch Dis Child* 77: 187.
5. Khundkar R, Wilson PA (2009) Basal cell carcinoma at the site of a nasal piercing. *J Plast Reconstr Aesthet Surg* 62: 557-558.
6. Ng MF, Clarkson JH, Hogg FJ (2010) Basal cell carcinoma arising from nasal piercing: Cause or coincidence. *J Plast Reconstr Aesthet Surg* 63: 153154.