

## Effectiveness of Direct Bite Raiser Onlays in Patients Affected By Temporomandibular Disorders: A Retrospective Observational Study

R Ursini<sup>1</sup>, F Agostini<sup>1\*</sup>, L Giuliante<sup>1</sup>, M Evangelista<sup>2</sup>, C Lajolo<sup>1</sup> and C Grippaudo<sup>1</sup>

<sup>1</sup>Institute of Clinical Dentistry, Catholic University of the Sacred Heart, Rome, Italy

<sup>2</sup>Institute of Anesthesiology, Resuscitation and Pain Therapy, Catholic University of the Sacred Heart, Rome, Italy.

Received July 06, 2018; Accepted August 26, 2018; Published October 30, 2018

### ABSTRACT

This retrospective observational study aims to assess the effectiveness of direct bite raiser onlays (DBRO) on pain and dysfunctional symptoms in patients affected by pain-related temporomandibular disorders (TMD). Furthermore, it wants to provide descriptive information about the clinical performance of the treatment.

We screened the electronic medical records of male and female patients with a diagnosis of pain-related temporomandibular disorders treated with DBRO. A data collection was performed from patients routinely gathered clinical records. A final sample of 43 patients was included in the analysis.

At the beginning of treatment all patients (100%) referred having pain and 12 patients (27.9%) complained about both pain and functional limitation. At the end of the treatment, 36 patients (83.7%) were symptom-free. In 5 subjects (11.6%), pain was still present but reduced in intensity. In 2 subjects (16.6%) functional limitations were improved but not completely resolved. During the treatment that lasted on average 8 months a mean of 7 checks have been carried out; the occlusal changes made on the DBRO had been on average 3. In 23 patients (53.5%) initial discomfort occurred after the beginning of treatment. The first beneficial effect was obtained on average on the fifth week of therapy.

The results of this retrospective observational study should be treated cautiously because of the limitations of the study design but suggest that patients with a diagnosis of pain-related temporomandibular disorders who are treated with direct bite raiser onlays experience a reduction in pain and dysfunctional symptoms.

**Keywords:** Temporomandibular disorders, TMD, Pain-related TMD, Occlusal appliance

### INTRODUCTION

The definition of “temporomandibular disorders” (TMDs) embraces a group of painful and/or dysfunctional musculoskeletal and neuromuscular conditions that involve the temporomandibular joints (TMJ), the masticatory muscles and associated head and neck structures that get together with them into anatomical and functional relationships. They have been identified as a major cause of non-dental pain in the orofacial region.

TMDs represent clusters of related disorders in the masticatory system with many common symptoms. Patients with TMDs most frequently present with pain, limited or asymmetric mandibular motion, and TMJ sounds. The pain or discomfort is often localized to the jaw, TMJ and muscles of mastication. Common associated symptoms include ear pain and stuffiness, tinnitus, dizziness, neck pain and headache [1].

TMDs have a considerable prevalence, reported to be between 3, 7 and 12%, with significant impact on physical and psychosocial factors [2]. A systematic review reported a prevalence of up to 9.7% for masticatory muscle pain, up to

11.4% for disc derangement disorders and up to 2.6% for TMJ pain disorders in the general population; while the prevalence of the different diagnoses in TMDs within patient populations varied widely, the results of a meta-analysis showed a prevalence of 45.3%, 41.1% and 30.1% for muscle disorders, disc derangements disorders and joint pain disorders, respectively [3]. TMDs are primarily a condition of young and middle-ages adults, rather than of children or the elderly, and are approximately twice more common in

**Corresponding author:** Francesca Agostini, Institute of Clinical Dentistry, Catholic University of the Sacred Heart, Rome, IT. Tel: +44 334 8461097; E-mail: fnc.agostini@gmail.com

**Citation:** Ursini R, Agostini F, Giuliante L, Evangelista M, Lajolo C, et al. (2018) Effectiveness of Direct Bite Raiser Onlays in Patients Affected By Temporomandibular Disorders: A Retrospective Observational Study. J Oral Health Dent, 1(2): 44-49.

**Copyright:** ©2018 Ursini R, Agostini F, Giuliante L, Evangelista M, Lajolo C, et al.. This is an open-access article distributed under the terms of the Creative Commons Attribution License, which permits unrestricted use, distribution, and reproduction in any medium, provided the original author and source are credited.

women than in men. TMDs are often remitting, self-limiting, or fluctuating over time; the progression to a potentially more serious chronic and disabling disease is relatively uncommon. Only 3.6% to 7% of individuals with TMDs are estimated to require treatment; for painful TMDs specifically, the most recent estimate for first onset was 3.9% [4].

Currently, the reference standards for a correct classification of TMDs are represented by the Diagnostic Criteria for Temporomandibular Disorders (DC/TMD) [5] developed by the International RDC/TMD Consortium Network of the International Association for Dental Research (IADR). The DC/TMD is a dual-axes taxonomic system that provides both the clinician and the researcher with evidence-based diagnostic criteria to be used in the evaluation of patients and populations involved in research projects.

Management goals for patients with TMDs include decrease pain, decrease adverse loading, restoration of function and resumption of normal daily activities. Most patients with this type of disorders achieve good symptom relief with conservative therapy. Long-term follow up of TMD patients shows that 50% to over 90% of the patients have few or no symptoms after conservative treatment. Stability is achieved in most cases between 6 and 12 months after the start of treatment [4].

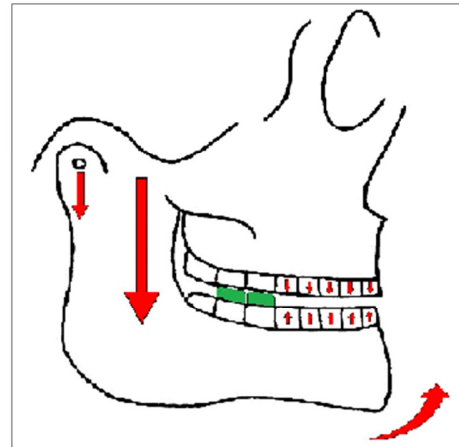
All therapies required for TMDs can be classified as causal or symptomatic treatment. The latter is directed to modify patient's symptomatology, but usually has no effect on disease etiology. Symptomatic treatments encompass patient education and self-management, pharmacotherapy, physical therapy and orthopedic appliance therapy.

Orthopedic appliances, including stabilization splint, anterior repositioning splint and distraction splint, are routinely used in the treatment of TMDs. They usually consist in removable acrylic resin appliances that cover the teeth, traditionally used to alter occlusal relationships and to redistribute occlusal forces, to prevent wear and mobility of the teeth, to reduce bruxism and parafunction, to treat masticatory muscle pain and dysfunction, to treat painful TMJs and to alter structural relationships in the TMJ. The most recent systematic reviews and meta-analysis did conclude that there is a moderate effect for reduction of pain with the use of splint therapy in TMDs.

Over time, stabilization splint has become one of the preferred therapies for treating patients with TMDs, and also one of the most studied. It represents the standard orthopedic appliance therapy for pain-related TMD. A recent systematic review by Pficer et al. [6] concluded that stabilization splint may have a significant role in treating TMDs in short term, while its effect is equalized with other therapeutic modalities in long term follow up.

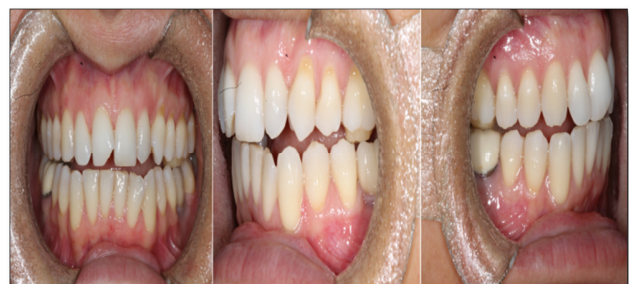Direct bite raiser onlays (DBRO) can be used as a therapeutic option in alternative to stabilization splint for the

symptomatic treatment of pain-related temporomandibular disorders. They stimulate the reprogramming of the neuromuscular engram, reduce abnormal muscular activity and produce neuromuscular balance. A component of uncontrolled extrusion of anterior teeth is present and is useful to stabilize therapeutic results (Figure 1).



**Figure 1.** Representation of the effects on articular, muscular and dental structures generated by the presence of direct bite raiser onlays in the oral cavity.

The chance to act 24 h a day is the main advantage of DBRO compared to the stabilization splint that is considered the standard treatment. The distal position, not very visible, and the biomimetic composite materials in which they are made minimize the aesthetic impact (Figure 2). For these reasons the gnathological therapy by DBRO is particularly recommended for acute and persistent pain-related TMD, in which the patient should wear the stabilization splint, much more unwieldy and unaesthetic, as many hours as possible throughout the day [7].



**Figure 2.** Frontal and lateral views of direct bite raiser onlays in the oral cavity.

The purpose of the current study is to collect non-controlled, therapy-related observations. The study aims to assess the effectiveness of direct bite raiser onlays on pain and dysfunctional symptoms in patients affected by pain-related temporomandibular disorders, and to provide descriptive information about the clinical performance of the treatment - the time frame necessary for therapy, the number of clinical

checks and occlusal adjustments performed during the treatment, the number of weeks necessary to obtain the first positive effects, any discomforts reported by the patients following the application of DBRO.

**MATERIALS AND METHODS**

This retrospective observational study was carried out in the Institute of Clinical Dentistry of Fondazione Policlinico Universitario A. Gemelli in Rome.

We searched the Orthodontics Department database from January 1, 2008 to May 31, 2018 to identify our study sample. We screened the electronic clinical records of male and female patients with a diagnosis of pain-related temporomandibular disorders - every subtype of myalgia, arthralgia, headache attributed to TMD, according to the DC/TMD - of any degree of severity, aged 0-65 years; only the ones who had been treated with direct bite raiser onlays were included in the analysis. Patients who had unsuccessfully undergone splint therapy or other TMD treatments in the past were not excluded. Patients whose medical records did not provided all the necessary information for the analysis were excluded. Patients with a history of facial trauma, systemic disease and comorbidities were excluded, as well as patients who had denied their consent to the treatment of clinical data.

A data collection was performed from selected patients' records:

- Pain at the beginning and at the end of treatment;
- Limitation in mandibular range of motion at the beginning and at the end of treatment;

- The maximum mouth opening value at the beginning and at the end of treatment (only if limitations in mandibular range of motion were present);
- Number of repetitive occlusal adjustment and/or resurfacing in course of treatment;
- Number of clinical checks carried out during the treatment;
- Time frame necessary for treatment;
- Discomforts at the beginning of treatment, related to the presence of the direct bite raiser onlays in the oral cavity;
- Number of weeks necessary to obtain the first benefit from the therapy.

We also gathered a range of other clinical and demographic data that were recorded in the patients' electronic notes, including sex, age at the initiation of treatment, diagnosis received (according to the DC/TMD), parafunctions, previous gnathological treatments attempted for the same disorder.

**RESULTS**

Patients selected from the archives were at first 49. After applying our inclusion criteria a final sample of 43 patients was retained. The main reason for excluding cases was related to having insufficient data from the clinical records.

The patients included in this study were 10 male and 33 female aged 12-65 years. The mean age of the participants was 34.88 years, SD=14.69. Detailed demographical and clinical information about the sample has been summarized in **Table 1**.

**Table 1.** Demographic and clinical information.

	<b>N=43</b>
<b>AGE</b>	
Mean (SD)	34.88 (14.68)
Range	12-65
<b>SEX (n (%))</b>	
Male	10 (23)
Female	33 (77)
<b>DIAGNOSIS (n (%))</b>	
Myalgia	20 (46.5)
Arthralgia	7 (16.3)
Myalgia+Arthralgia	16 (37.2)
Headache attributed to TMD	14 (32.5)
<b>PARAFUNCTIONS (n (%))</b>	20 (46.5)
<b>PREVIOUS GNATHOLOGICAL THERAPY (n (%))</b>	20 (46.5)

At the beginning of treatment all patients (100%) referred having pain and 12 patients (27.9%) complained about both pain and functional limitation.

At the end of the treatment, 36 patients (83.7%) were symptom-free. In 5 subjects (11.6%) pain was still present; in 2 subjects (16.6%) functional limitations were improved but not completely resolved.

The maximum mouth opening values at the end of treatment with direct bite raiser onlays in patients with functional limitations had increased compared to the beginning of therapy, with a mean difference of  $9.5 \pm 4.96$  mm.

For 6 patients the treatment period lasted less than 3 months (13.9%), for 9 patients between 3 and 6 months (20.9%), for 14 patients between 6 and 9 months (32.5%), for 8 patients between 9 and 12 months (18.6%) and for 6 patients more than 12 months (13.9%). During the treatment, that lasted on average 8.34 months (SD=4.59), a mean of 7.09 checks (SD=2.89) have been carried out; the occlusal changes made on the DBRO had been on average 3.16 (SD=2.08).

In 23 patients (53.5%) initial discomfort occurred after the beginning of treatment. The first beneficial effect was obtained on average on the fifth week of treatment.

## DISCUSSION

Direct bite raiser onlays (DBRO) are occlusal wedges realized directly in composite material bonded to the chewing surface of the teeth. Their occlusal portion must be flat to allow freedom in protrusive and lateral jaw movements; furthermore, it must ensure equally distributed inter-arch contacts to lend occlusal and orthopedic jaw balance. The height of the onlays must be the minimum to consent the absence of contacts between the teeth during the closing and eccentric mandibular movements but avoiding increases in the vertical dimension that do not respect the freeway space (physiologically from 2-5 mm). DBRO must be realized on the upper or lower first and/or second molar - depending on the occlusal conditions of the individual patient - to ensure maximum orthopedic jaw balance when the dental arches collide. DBRO therapy is recommended for the treatment of severe pain-related temporomandibular disorders for which resolution stabilization splint worn 24 h a day would be desirable.

The structural features of direct bite raiser onlays and stabilization splints are conceptually superimposable. The stabilization splint - acting like an occlusal and articular release - allows, through a smooth contact surface without forced gear, the suppression of anomalous contact causing nociceptive information that generate improper muscle work, the occlusal stabilization preventing unwanted slipping, the relaxation and the suppression of pain due to the muscular hyperactivity, the restoration of correct joint spaces lost for occlusal reasons, the control of parafunctional habits.

The principles by which the DBRO function and exert their therapeutic potential are similar to those of the stabilization splint: the occlusal release through the mechanical interposition of the onlays between the arches, which causes an interruption of the neuromuscular engram built around the previous maximum intercuspation occlusion; the reduction of abnormal activity of the muscles participating in the masticatory functions, due to the increase in the vertical dimension generated by the thickness of the onlays; a mandibular ante-rotation, which results in a minimal articular distraction; the release of cervical tensions and a certain degree of postural adaptation, due to the rotation of the skull on the occiput secondary to the mandibular rotation; a component of non-controlled extrusion of the mesial teeth that allows an increase in the vertical dimension of occlusion, which is useful to a certain stabilization of the results over time [7]. The latter feature, which belongs exclusively to direct bite raiser onlays, means that this type of symptomatic therapy is more invasive than other therapies classically considered reversible, whose use is recommended especially in the initial phases of DTM management - such as self-management, pharmacotherapy, physiotherapy, occlusal devices. Precisely this aspect, although it connotes this therapy as not really conservative, means that direct bite raiser onlays are recommended above all in subjects that have unsuccessfully undergone reversible treatments and in subjects who do not intend to undergo any phase of stabilization of the results afterwards to the gnathological therapy.

Because of the current lack of evidence from observational studies on direct bite raiser onlays it is difficult to compare and contrast our results with previously published papers.

Treatment outcomes were assessed by observing pain reduction and functional limitation. In a systematic review of Pfcifer et al. [6] on stabilization splints pain reduction was taken as a measure of outcome and was defined as an improvement or reduction in signs and symptoms at the end of treatment. In our study, the pain reduction was measured categorically, considering the symptom as "present" whenever pain of any degree of intensity was reported and as "absent" only in case of total absence of any type of algic symptomatology. The functional limitation was also measured categorically, in relation to the maximum mouth opening (MMO) expressed in millimeters; an MMO of 40 mm was taken as a critical value, considering the functional limitation as "present" for values of MMO lower than 40 mm and as "absent" for values greater than or equal to 40 mm.

Maximum mouth opening is an important diagnostic reference for dental clinicians as a preliminary evaluation of mandibular function. Limited mouth opening during mandibular movements may result from temporomandibular disorders, oral submucous fibrosis, rheumatic disease, infection, malignancies or facial trauma. Establishing a

normal range for MMO could allow dental clinicians to objectively evaluate the treatment effects, even if in the concrete it is complex because of the wide interindividual variability linked to age, sex, ethnicity, joint condition, mandibular size, cranial base size, body height and weight [8]. In this study the cut off value of physiological maximum mouth opening was set at 40 mm, according to Okeson [9].

Our primary endpoint analysis shows that the treatment with direct bite raiser onlays in 36 patients with pain-related TMD was associated with the remission of pain and dysfunctional symptoms. Therefore, in our sample of 43 subjects, the therapy had a good success rate, both with respect to the algic symptomatology - 38 out of 43 patients (81.4%) denied the presence of pain at the end of the therapy - and to the functional limitation - 10 out of 12 patients (83.3%) had recovered a maximum mouth opening equal to or greater than 40 mm at the end of treatment. The values of the maximum mouth opening in the subjects presenting it limited at the beginning of the treatment showed an improvement of on average  $9.5 \pm 4.96$  mm.

The clinical performance of a Tanner stabilization splint therapy was evaluated in a study by Zonnenberg and Mulder [10] observing the actual timeframe necessary for treatment and the need to do repetitive occlusal adjustments and/or resurfacing of the split in the course of therapy. In our study we also considered the number of checks performed during treatment.

The data collected showed that the therapy lasted on average 8 months with a large variability, since only in 14 subjects (32.5%) the treatment lasted between 6 and 9 months. In total, for 37 patients, the treatment ended within 12 months (86%). During this time, about on average 7 checks were carried out, normally on a monthly basis. During these checks, excluding the session of construction and that of complete removal, the onlays have undergone on average about 3 adjustments, both in addition and in subtraction way. The latter outcome may suggest that therapy with direct bite raiser onlays is not very efficient; it is however necessary to remember that, compared to an occlusal splint made in the laboratory in an indirect way, the onlays are built directly in the patient's mouth and this makes it necessary to have more adjustments to obtain an ideal surface and height.

In 23 patients (53.5%) initial discomfort occurred after the beginning of treatment. In particular it has been reported difficulties in mastication, phonation or swallowing, sensitivity to the carrier teeth of the onlays, fatigue and muscle pain caused by transitory parafunctional activities triggered by the presence of the onlays themselves. However, generally, these discomforts disappeared after the first 7-10 days from the realization of the DBRO.

The first beneficial effect of therapy has been reported to be around the fifth week from the start of treatment. This figure, however, is probably affected by the fact that the first

check took place roughly 30-35 days after making the onlays. We can imagine that symptoms relief can occur before five weeks.

Because of the limitations of the retrospective observational study design and the relatively small sample size, our results should be treated with caution, particularly as any changes in pain and dysfunctional symptoms may be due to numerous possible extraneous influences. We cannot establish with certainty that direct bite raiser onlays reduce the symptomatology of pain-related TMDs or are more or less effective than other therapy because this is a non-controlled study without a comparison group. However, since this study was expected to collect non-controlled therapy-related observation, all findings need to be confirmed in future experimental studies, accompanied by appropriate diagnostic tests. Direct bite raiser onlays appear to be promising efficient means for the treatment of patients with pain-related TMDs, and their efficacy makes them eligible to be tested in trials to provide higher levels of evidence.

## CONCLUSION

Because of the limitations of the retrospective observational study, our results should be treated with caution, particularly as any changes in pain and dysfunctional symptoms may be due to numerous possible extraneous influences.

Despite these limitations, this observational study suggests that direct bite raiser onlays therapy in patients with a diagnosis of pain-related temporomandibular disorders is likely to be associated with a reduction of pain and limitation in mandibular range of motion.

## REFERENCES

1. Scrivani SJ, Keith DA, Kaban LB (2008) Temporomandibular disorders. *N Engl J Med* 359: 2693-2705.
2. Gil-Martinez A, Paris-Alemay A, Lopez-de-Uralde-Villanueva I, La Touche R (2018) Management of pain in patients with temporomandibular disorder (TMD): Challenges and solutions. *J Pain Res* 16: 571-587.
3. Manfredini D, Guarda-Nardini L, Winocur E, Piccotti F, Ahlberg J, et al. (2011) Research diagnostic criteria for temporomandibular disorders: A systematic review of axis I epidemiologic findings. *Oral Surg Oral Med Oral Pathol Oral Radiol Endod* 112: 453-462.
4. De Leeuw R (2018) Klasser GD. Orofacial pain: Guidelines for assessment, diagnosis, and management/American Academy of Orofacial Pain. Sixth Edition. Hanover Park, IL: Quintessence Publishing Co, Inc.
5. Schiffman EL, Ohrbach R, Truelove E, Look J, Anderson G, et al (2014) Diagnostic criteria for temporomandibular disorders (DC/TMD) for clinical and research applications: Recommendations of the

International RDC/TMD Consortium Network and Orofacial Pain Special Interest Group. *J Oral Facial Pain Headache* 28: 6-27.

6. Pficer JK, Dodic S, Lazic V, Trajkovic G, Milic N, et al. (2017) Occlusal stabilization splint for patients with temporomandibular disorders: meta-analysis of short and long term effects. *PLoS One*.
7. Perez PR (1996) Apport de l'orthopédie mandibulaire dans le traitement des dérangements des ATM: principes (1<sup>o</sup> partie). *Le Journal de l'Edgewise*.
8. Li XY, Jia C, Zhang ZC (2017) The normal range of maximum opening and its correlation with height or weight in the young adult chinese population. *J Dent Sci* 12: 249-252.
9. Okeson JP (2014) *Il trattamento delle disfunzioni e dei disordini temporomandibolari*. Bologna: Edizioni Martina.
10. Zonnenberg AJJ, Mulder J (2014) The efficacy of a specific stabilization splint. *Cranio* 32: 68-74.